



## Morphomolecular alterations in the skin mucosa of Atlantic salmon (*Salmo salar*) after exposure to peracetic acid-based disinfectant

Carlo C. Lazado<sup>a,\*</sup>, Sindre Haddeland<sup>b</sup>, Gerrit Timmerhaus<sup>a</sup>, Ragnhild Stenberg Berg<sup>c</sup>, Grigory Merkin<sup>d</sup>, Karin Pittman<sup>b,d</sup>, Lars-Flemming Pedersen<sup>e</sup>

<sup>a</sup> Nofima, Norwegian Institute of Food, Fisheries and Aquaculture Research, 1433, Ås, Norway

<sup>b</sup> Department of Biological Sciences, University of Bergen, 5006, Bergen, Norway

<sup>c</sup> Nofima, Norwegian Institute of Food, Fisheries and Aquaculture Research, 9019, Tromsø, Norway

<sup>d</sup> Quantidoc AS, 5006, Bergen, Norway

<sup>e</sup> Technical University of Denmark, Section for Aquaculture, 9850, Hirtshals, Denmark

### ARTICLE INFO

#### Keywords:

Aquaculture  
Disinfectant  
Mucous cells  
Skin health  
Peracetic acid  
Hydrogen peroxide

### ABSTRACT

Peroxygen-based chemotherapeutants are commonly used in treating ectoparasitic infections in fish. A majority of relevant studies address the effects of these substances on the targeted causative agents, but little is known about their physiological impacts on the host organism. This study documented the changes in the skin of Atlantic salmon (*Salmo salar*) exposed to peracetic acid (PAA), a peroxygen disinfectant with potent oxidative properties. Fish were exposed to three therapeutic concentrations of PAA-based disinfectant: 0, 0.6, and 2.4 ppm. The initial exposure time was 5 min, and two weeks after, fish were re-exposed to the same doses for 30 min. Skin colour was not dramatically affected by the PAA treatments. No gross pathologies, lesions, or wounds were observed in the skin of sampled fish. Histological evaluation revealed that fish treated with PAA appeared to have rough epidermal surface compared with the 0 ppm group, especially after the re-exposure. Morphometrics of mucous cells did not markedly vary amongst the treatments, although the group treated with 2.4 ppm displayed a relatively larger mucous cells 2 weeks after the first exposure. Transcriptional analysis was conducted for key markers that were previously identified to be involved in the mucosal response to PAA, and the results revealed that proteolysis-related genes were modulated more remarkably during the first exposure than during re-exposure. These data revealed that therapeutic doses of PAA induced morphomolecular changes in the skin of salmon, although the magnitude of alteration was marginal.

An ideal therapeutant in aquaculture should not only be effective against the target agent but also it should not have inherently detrimental effects on the host organism or the environment. Many of the chemotherapeutants currently in use are effective against major aquaculture pathogens (Burridge et al., 2010; Luis et al., 2019; Vincent et al., 2019), but there remain substantial knowledge gaps in how they impact fish physiology, both short-term and long-term. One reason may be that the classical indicator of treatment success in aquaculture is the resolution of clinical signs of the disease, whereas the physiological responses of fish to the treatments are often not well documented. A better understanding of how fish respond to a treatment would provide opportunities for risk assessment, which would in turn, foster more sustainable use of chemotherapies in aquaculture.

Peroxygen-based disinfectants are frequently applied as bath chemotherapeutants in fish farming, and hydrogen peroxide (H<sub>2</sub>O<sub>2</sub>) is the

most common one. These compounds are also referred to as oxidative biocides, and they influence cellular activity via different mechanisms, including peroxidation and disruption of membrane layers, oxidation of oxygen scavengers and thiol groups, enzyme inhibition, oxidation of nucleosides, impaired energy production, disruption of protein synthesis, and, ultimately, cell death (Finnegan et al., 2010). Peracetic acid (PAA) a peroxygen compound with strong oxidative potential, is currently gaining popularity as a sustainable disinfectant in aquaculture because of its potency at lower concentrations and rapid degradation to neutral compounds (Pedersen, Lazado, 2020; Pedersen et al., 2013; Pedersen et al., 2009). Commercial PAA-products contain PAA, H<sub>2</sub>O<sub>2</sub>, water and acetic acid in an equilibrium mixture. Moreover, it has a broad spectrum of biocidal activity against pathogens that present significant challenges in fish farming, including *Ichthyophthirius multifiliis*, *Aeromonas salmonicida*, *Saprolegnia* sp. and *Flavobacterium*

\* Corresponding author.

E-mail address: [carlo.lazado@nofima.no](mailto:carlo.lazado@nofima.no) (C.C. Lazado).

<https://doi.org/10.1016/j.aqrep.2020.100368>

Received 19 February 2020; Received in revised form 8 May 2020; Accepted 10 May 2020

Available online 19 May 2020

2352-5134/ © 2020 The Authors. Published by Elsevier B.V. This is an open access article under the CC BY license (<http://creativecommons.org/licenses/by/4.0/>).

columnare, to name a few (Good et al., 2020; Marchand et al., 2012). However, physiological studies on PAA use in fish are limited.

At present, PAA-based disinfectant is being explored as an alternative therapeutant for amoebic gill disease (AGD), which is an ectoparasitic infestation in Atlantic salmon (Lazado et al., 2019). Earlier reports showed that PAA exposure resulted in minimal physiological alterations, and exposed fish were able to mount appropriate responses to the biological pressures of PAA (Gesto et al., 2018; Liu et al., 2020a; Soleng et al., 2019). However, our current understanding is incomplete, especially regarding how the skin mucosa—one of the barrier surfaces that directly interacts with the compound—responds to the presence of the oxidative compound. Thus, we report on how the skin of Atlantic salmon (*Salmo salar*) responded to different therapeutic doses of PAA by investigating histo-structural alterations and molecular responses following two exposures.

Salmon smolts (weight:  $150.3 \pm 5.6$  g, mean  $\pm$  SE) were purchased from Danish Salmon A/S (Hirtshals, Denmark) and reared in the aquaculture recirculation facility of DTU Aqua in Hirtshals. Sixty fish were stocked in each of the six 1-m<sup>2</sup> holding tanks (water volume  $\approx$  600 L) with full-strength seawater (33 ppt) and were allowed to acclimate to laboratory conditions for three weeks. Water temperature was maintained at  $15 \pm 1$  °C, dissolved oxygen at  $> 80$  % saturation and pH at 7.5–7.7. Fish were exposed to three different therapeutic doses of PAA: 0, 0.6, and 2.4 ppm. The chosen test concentrations were based on efficacy against major aquaculture pathogens (Straus et al., 2018), earlier applications in another salmonid species (rainbow trout) (Davidson et al., 2019; Hushangi, Hosseini Shekarabi, 2018; Liu et al., 2020b), and *in vitro* inhibitory activity against *Neoparamoeba perurans*, the causative agent of AGD, where PAA is being developed as a potential treatment (Breiland et al., 2019). PAA-based disinfectant (Divosan Forte™) was provided by Lilleborg AS (Oslo, Norway). The disinfectant is a stabilised PAA solution, and the actual concentration of PAA in the product was determined by a two-step titration at the DTU Aqua Laboratory (Pedersen, Lazado, 2020). Each treatment had two replicate tanks. For the first exposure, fish were exposed to PAA for 5 min, and two weeks after, the groups were exposed again to the same concentration but for 30 min. Briefly, fish from a holding tank were transferred to an exposure tank with similar water conditions and technical specifications. Water flow was stopped and PAA was added to the water to achieve the desired nominal concentration, and aeration was provided to facilitate mixing for the duration of each exposure (additional details of the trial are described in Soleng et al. (Soleng et al., 2019)). After the exposure period, fish were returned to the holding tanks for recovery. For the chemical behaviour of PAA in the water during the trial, including its degradation through time, readers are referred to (Pedersen, Lazado, 2020).

Prior to tissue collection, fish (5 fish per replicate tank; starved for 24 h prior to sampling) were humanely euthanised by an overdose of 20 % benzocaine solution, and the whole body of each fish for sampling was then photographed in a box with controlled light conditions (Canon EOS 60S, manual settings f/11, 1/8 s, ISO200, 23 mm). Individual photos were processed with an R-script to crop out an image of the skin in the centre of the fish with a width of 600 pixels and spanning over 60 % of the height of the body. The cropped pictures of skin were analysed by calculating the mean intensities for red, green and blue (RGB).

Skin samples from the dorsal region ( $\sim 8$ cm  $\times$  4cm) were collected for histological and qPCR analyses. A small portion of the skin was suspended in RNAlater® (Sigma-Aldrich, USA) and left overnight to allow for penetration at room temperature followed by storage at  $-70$  °C until RNA isolation. The remaining skin analyses focused on the mucosal epithelium. The skin sample was cut in two, with one half for Quantidoc's standard mucosal cell mapping (giving 1–2 square cm of surface area using tangential sectioning), and the other half for histological skin health scoring at Nofima (traditional transverse sectioning giving about 2 square microns of surface area). Both samples were preserved in neutral buffered formalin.

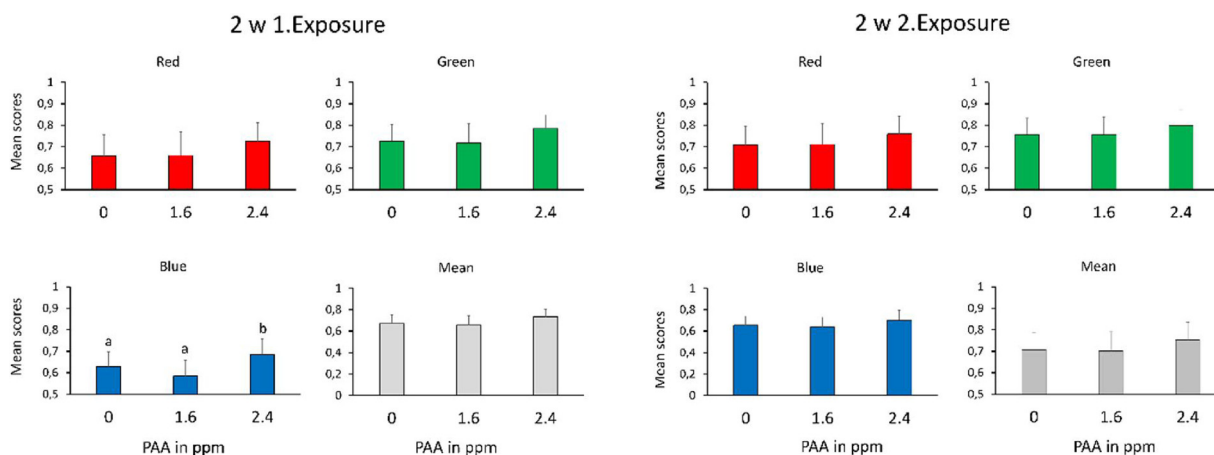
For Quantidoc skin samples, the tissues were embedded in paraffin, sliced tangentially into 3- $\mu$ m-thick sections, and stained with Periodic Acid Schiff-Alcian Blue (PAS-AB) according to Quantidoc's protocol (Pittman et al., 2013, 2011). All samples were scanned by a Hamamatsu slide scanner to obtain high-resolution digital images (NDPI format). Mucosal mapping with Veribarr™ and Mucomaster™ were used to analyse and estimate the volumetric density and the mean area of mucous cells in the skin mucosa. The mean area and volumetric density were used to calculate the barrier status of the mucosal epithelium as  $1/(\text{Area/Density}) \times 1000$ , which indicates the quality of the barrier tissue.

Samples for skin health scoring were processed and photographed as described previously (Sveen et al., 2018). The section was scored by an impartial evaluator (no prior knowledge of sample treatment) using a 0 to 3-point system, with 0 indicating healthy skin and 3 indicating severely damaged conditions. Two key epidermal features were characterised: general appearance of the epidermis and epidermal surface characteristics (Supplementary File 1). Skin colour analysis and both histological characterisations were performed using samples collected 2 weeks after each exposure. We earlier reported that the effects of PAA on selected stress parameters were still persistent after 14 days post treatment (Soleng et al., 2019), hence, the results here will offer additional insights into the short-to-mid-term effects of PAA.

The RNA isolation, complementary DNA (cDNA) synthesis, and quantitative polymerase chain reaction (qPCR) assay were described in detail in a previous publication (Soleng et al., 2019). Briefly, RNA from skin samples was isolated using Agencourt® RNAdvance™ Tissue Total RNA Purification Kit (Beckman Coulter Inc., CA, USA). Total RNA was reverse transcribed to cDNA using a High-Capacity cDNA Reverse Transcription Kit (Applied Biosystems, USA) from a 200-ng RNA template. Quantification of the gene transcript by real-time qPCR was performed with a QuantStudio 5 Real-Time PCR system (Applied Biosystems) using Power SYBR Green PCR Master Mix (Applied Biosystems). Ct values were generated using a threshold fluorescence of 0.1, and the relative gene expression was calculated by the delta-delta Ct method (Nagasawa et al., 2012). The genes measured included *haptoglobin-like (hpl)*, *complement factor-like H (cfhl)*, *chymotrypsin B (ctrb)*, and *trypsin II (trp-ii)*, previously identified from a microarray data set as being responsive to PAA treatment (Lazado et al., 2019). *Elongation factor 1 alpha (elf1a)* was used as an internal control. Primer sequences are provided in Supplementary File 2. Skin samples collected at 48 h and 2 weeks after each exposure were used for gene expression analysis.

PAA exhibits bleaching power (Hickman, 2002), which might present potential side effects when salmon are bathed in this compound. Regardless of the treatment dose and duration, we found that skin colour (individual RGB and mean RGB) was not significantly affected by PAA except a transient response of the blue channel at two weeks after the first exposure, though not after the second exposure (Fig. 1). The blue colour is a product of blue iridophores reflecting light and black melanophores absorbing light across the spectrum (Nüsslein-Volhard, Singh, 2017). The blue colour of salmon skin that was exposed to 2.4 ppm for 5 min was significantly lighter than that of the other two treatment groups, suggesting either expansion of the iridocytes or reduction of melanocytes, as well as an interaction between skin colour and the stress response (Thorsen, 2019). Although PAA treatment may have some colour-bleaching effect, the fish recovered, and re-exposure did not exacerbate the impact, suggesting that the response was likely an acute adaptation to the PAA bath treatment.

No external skin lesions or wounds were observed on the fish sampled, although scale loss was prominent in all treatment groups, which can be ascribed to handling during exposure (Lazado et al., 2019). Traditional histopathology of the skin did not identify any major pathological alterations. Skin health scoring, which mainly evaluated the quality of surface structure revealed some minor changes following treatments (Fig. 2A, B). The scores for general appearance were between 1–2, indicating parts of the epidermis were missing, for groups treated with PAA at 2 weeks after the second exposure (Fig. 2D, E).

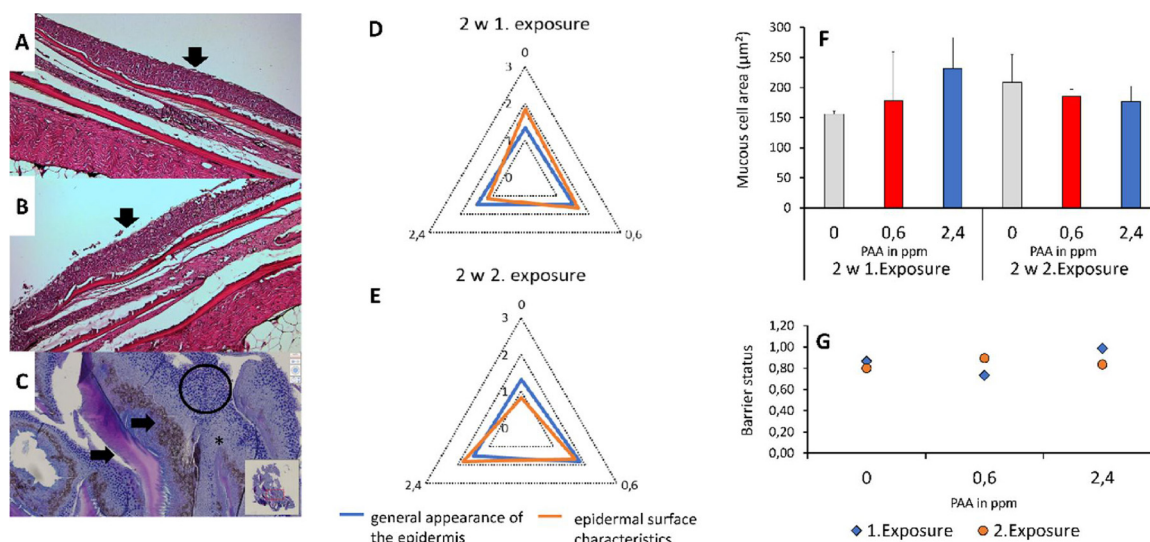


**Fig. 1.** Skin colour analysis of PAA-exposed fish 2 weeks after each exposure. Fish were exposed to 3 PAA doses: 0, 0.6 and 2.4 ppm. Each fish for sampling (n = 10 fish per treatment group) were photographed, processed and the values are presented as mean score (mean ± SD) of individual colour panel (Red, Green, Blue = RGB) as well as the overall RGB mean value of the picture. A higher value represents lighter/brighter colours, a lower value indicate a darker colour. Different letters indicate significant inter-treatment differences at P < 0.05 as inferred by one-way ANOVA followed by Holm-Sidak test. (For interpretation of the references to colour in this figure legend, the reader is referred to the web version of this article).

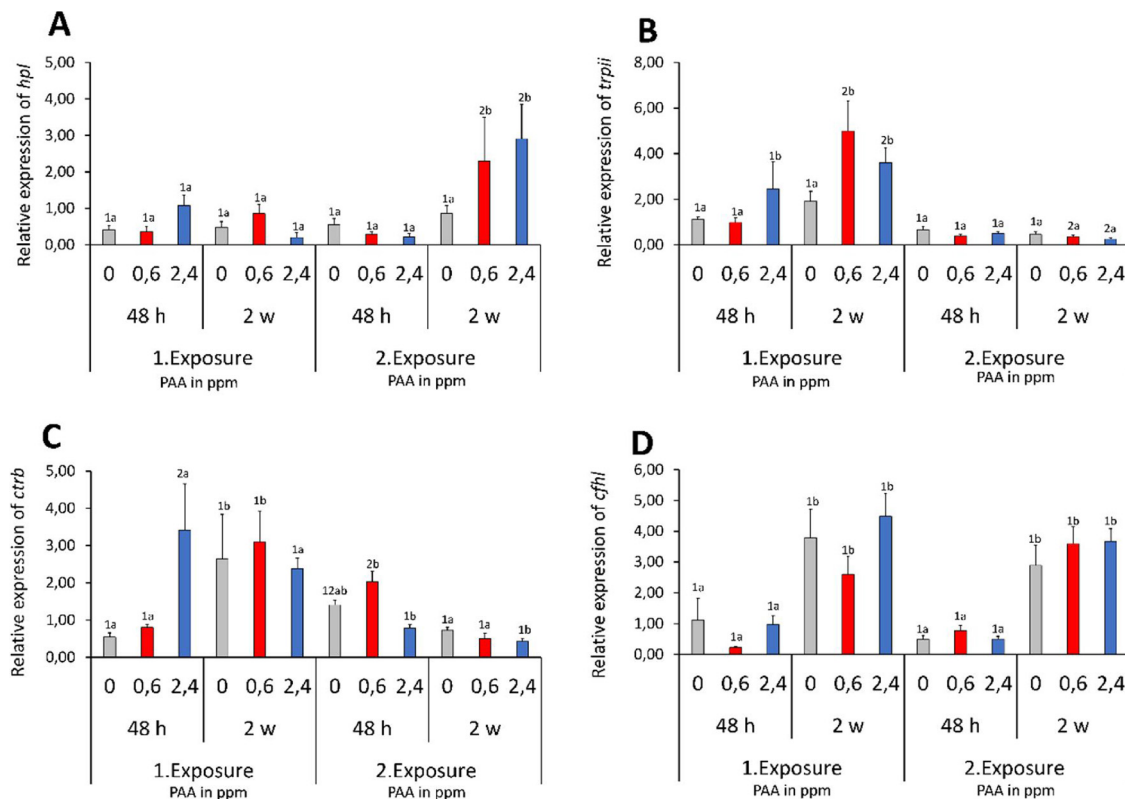
However, there were no significant inter-treatment differences. Both the 0.6 and 2.4-ppm groups had scores of 1–2 in their epidermal surface appearance, indicating rough cells at the surface, and around 50 % of the evaluated epidermal surface was structurally compromised. It is not clear whether this cutaneous result after treatment is worsened by repeated exposure since we only examined 2 exposures.

The dynamic behaviour of mucous cells following treatment and in response to different environmental stimuli has clinical significance and have thus been used to characterise mucosal health in skin, gills and intestines (Dang et al., 2019; Pittman et al., 2013, 2011). The mean mucous cell area amongst the groups were 188.71 ± 38.9 μm<sup>2</sup> at 2 weeks after the first exposure, while for the second exposure it was around 190.50 ± 16.8 μm<sup>2</sup> (Fig. 2C,F), which were within the normal range for skin mucous cells in this fish size (Quantidoc database).

Though there was an apparent tendency that mucous cell area increased in size at increasing PAA concentration during the first exposure, there were no significant inter-treatment differences. Interestingly, an opposite tendency was documented during the second exposure, nonetheless, the changes remained not statistically significant. The mucous cell density did not significantly vary amongst the treatment groups, either 2 weeks after the first or second exposures. Barrier status is a mathematical representation of the barrier quality of the epithelial surface as a function of mucous cell size and volumetric density. PAA treatments did not significantly affect the skin mucosal barrier status of salmon (Fig. 2G), corroborating the skin health scoring (Fig. 2D, E). The two methods – qualitative (*skin health scoring*) and quantitative (*mucosal mapping*), revealed the minimal changes associated with PAA exposure at therapeutic doses, thus indicate that the treatments did not



**Fig. 2.** Skin histomorphometry of PAA-exposed fish 2 weeks after each exposure. A-C: Representative photomicrographs of salmon skin exposed to PAA. A,B: Traditional cross-section of the skin stained with haematoxylin and eosin. A: Healthy-looking epithelium with a smooth surface and well-defined structure (arrow head), typical in 0 ppm group; B: Moderately compromised epithelium with a rough surface (arrow head), common in fish exposed to 2.4 ppm PAA. C: A tangential section of the skin from 0 ppm group, stained with PAS-AB to reveal the mucous cells (dark blue-coloured cells, encircled). Black = pigment (arrow head), pink = scales (arrow head), medium blue = epithelium (asterisk, \*). A typical appearance of skin with good barrier status as indicated by the area and volumetric density of the mucous cells. D, E: Radar charts showing the quality of skin epithelial surface as scored 0 to 3, with 3 as the worst. F, G: Mucosal mapping of the skin surface. F: Mean mucous cell area (mean ± SD) and G: Barrier status, a mathematical representation developed by Quantidoc AS for the quality of mucosal barrier as a function of mucous cell area and density. No significant inter-treatment differences were identified by one-way ANOVA followed by Holm-Sidak test (P < 0.05). (For interpretation of the references to colour in this figure legend, the reader is referred to the web version of this article).



**Fig. 3.** Gene expression profiles in the skin of salmon exposed to different levels of PAA (0, 0.6, 2.4 ppm), either for 5 min (1.Exposure) or 30 min (2.Exposure). Values are mean  $\pm$  SEM of eight individual fish. Two-way ANOVA ( $P < 0.05$ ) followed by Holm-Sidak test was used to identify differences between treatments and sampling points. Different numbers signify significant differences between treatments within a sampling point, whilst different letters indicate significant differences within a treatment through time. A: *haptoglobin-like (hpl)*; B: *trypsin II (trpII)*; C: *chymotrypsin B (ctrb)*; D: *complement factor-like H (cfhl)*.

compromise the quality of the skin epithelial layer.

A global transcriptomic study on salmon identified several gene markers for PAA response in the skin (Lazado et al., 2019), and the expression of four of them was quantified by qPCR in this study. In general, the transcription of marker genes in the skin was significantly modulated when fish were exposed to 2.4 ppm of PAA. In a previous study, fish exposed to the PAA concentrations used in the present study had elevated levels of systemic total antioxidant capacity, indicating that oxidative stress responses had been activated (Soleng et al., 2019). Besides their well-documented role in inflammation, *haptoglobins* are acute-phase proteins that participate in anti-oxidant response (Bertaggia et al., 2014). *Hpl* transcript level was significantly elevated in both PAA-exposed groups relative to the control group only at 2 weeks after the second exposure (Fig. 3A). This profile suggests that *hpl* may not likely be involved in the acute response but rather during the physiological responses involved in the recovery from PAA exposures.

The mucus-secreting cell layer of salmon skin produces trypsin (Braun et al., 2006), which has been identified to be involved in the defence repertoire of the epithelial surface (Firth et al., 2000). Two trypsin genes were identified to be responsive to PAA, *chymotrypsin B (ctrb)* and *trypsin II (trp-II)* (Lazado et al., 2019), and their expression in the present study revealed that they may be more responsive during the first exposure than during the second exposure with longer duration (Figs. 3B, C). Significantly elevated transcription was observed for *trpII1* in both PAA-exposed groups 2 weeks after the first exposure, while significantly higher expression of *ctrb* was observed 48 h after the first exposure, but only in the 2.4-ppm group.

Proteolytic responses are an important secondary defence against oxidative stress by destroying oxidised and damaged proteins, thus preventing intracellular accumulation (Mehlhase, Grune, 2002). It was interesting to observe the modulated responses from the two trypsin genes during the first exposure since a published companion study

showed that the systemic alteration of oxidative stress was more pronounced after the second exposure (Soleng et al., 2019). Although both genes have other functions, their known involvement in oxidative stress allowed us to hypothesise that *trpII* and *ctrb* are very sensitive to PAA and might have active roles in the proteolysis-mediated response to protect the mucosa from acute PAA-induced oxidative stress. Their unresponsiveness following the re-exposure suggests that secondary exposure to PAA did not have an additive effect, and the mucosa recognised the signal as safe, at least in the proteolytic system. *Cfhl* did not exhibit significant inter-treatment variations, but temporal variability was apparent (Fig. 3D).

In conclusion, the results of the present study indicate that the skin of salmon responded, though minimally, to varying therapeutic concentrations of PAA-based disinfectant. There were no pronounced and severe histostructural changes (i.e. surface quality and mucous cell morphometrics) after the exposures. In addition, the expression of four PAA response marker genes revealed no general tendency though provided some indications that PAA exposure can differentially impact their transcription. Collectively, the magnitude of alternations related to PAA response in terms of skin colour, histostructure and gene expression was marginal, hence, substantiating further the earlier evidence that PAA does not present a significant challenge to the mucosal health of salmon in the tested concentration range. Since PAA-based disinfectants are available commercially in different strengths, composition and stabilisers, the changes documented here are to be considered for the tested product only. It would be interesting to compare different commercial PAA products to benchmark the responses of salmon skin to peracetic acid.

#### Credit author statement

C.C. Lazado: Acquisition of funding, project administration, design



of experiment, sample collection, lab analysis, data analysis, writing of the manuscript

S. Haddeland: Sample collection, lab analysis, data analysis, writing of the manuscript

G. Timmerhaus: Design of experiment, sample collection, data analysis, data presentation, writing – review & editing

R.S. Berg: Lab analysis, data analysis, writing – review & editing

G. Merkin: Lab analysis, data analysis, data presentation

K. Pittman: Design of experiment, sample collection, data analysis, writing of the manuscript

L.F. Pedersen: Design of experiment, sample collection, data analysis, writing of the manuscript

### Declaration of Competing Interest

K. Pittman developed mucosal mapping in 2010 which has since been made commercially available as Veribarr™, under Quantidoc AS where she is the Chief Scientific Officer. K. Pittman and G. Merkin work for Quantidoc AS.

### Acknowledgements

This study was financed by The Norwegian Seafood Research Fund project PERAGILL (FHF 901472). The mucosal mapping part of the paper was included in S. Haddeland's M.Sc. thesis, which was submitted to the Department of Biological Sciences at the University of Bergen. We would like to thank Rasmus Frydenlund Jensen and Ole Madvig Larsen of DTUA Aqua (Hirtshals, Denmark) for their assistance in fish husbandry. We would like to thank Lilleborg AS (Lisbeth Rørmark) for providing the PAA used in the study. The mention of trade names or commercial products in this article is solely for the purpose of providing specific information and does not imply recommendation or endorsement by Nofima or DTU Aqua.

### Appendix A. Supplementary data

Supplementary material related to this article can be found, in the online version, at doi:<https://doi.org/10.1016/j.aqrep.2020.100368>.

### References

- Bertaggia, E., Scabia, G., Dalise, S., Lo Verso, F., Santini, F., Vitti, P., Chisari, C., Sandri, M., Maffei, M., 2014. Haptoglobin is required to prevent oxidative stress and muscle atrophy. *PLoS One* 9 e100745–e100745.
- Braun, R., Arnesen, J.A., Rinne, A., Hjelmeland, K., 2006. Immunohistological localization of trypsin in mucus-secreting cell layers of Atlantic salmon, *Salmo salar* L. *J. Fish Dis.* 13, 233–238.
- Breiland, M.W., Hytterød, S., Mohammad, S., Soleng, M., Johansen, L.-H., Rørmark, L., Pedersen, L.-F., Lazado, C.C., 2019. Peracetic acid and its anti-parasitic activity against *Neoparamoeba perurans*, the causative agent of amoebic gill disease. *Frisk Fisk*.
- Burridge, L., Weis, J.S., Cabello, F., Pizarro, J., Bostick, K., 2010. Chemical use in salmon aquaculture: a review of current practices and possible environmental effects. *Aquaculture*. 306, 7–23.
- Dang, M., Pittman, K., Bach, L., Sonne, C., Hansson, S.V., Søndergaard, J., Stride, M., Nowak, B., 2019. Mucous cell responses to contaminants and parasites in shorthorn sculpins (*Myoxocephalus scorpius*) from a former lead-zinc mine in West Greenland. *Sci. Total Environ.* 678, 207–216.
- Davidson, J., Summerfelt, S., Straus, D.L., Schrader, K.K., Good, C., 2019. Evaluating the effects of prolonged peracetic acid dosing on water quality and rainbow trout *Oncorhynchus mykiss* performance in recirculation aquaculture systems. *Aquac. Eng.* 84, 117–127.
- Finnegan, M., Linley, E., Denyer, S.P., McDonnell, G., Simons, C., Maillard, J.-Y., 2010. Mode of action of hydrogen peroxide and other oxidizing agents: differences between liquid and gas forms. *J. Antimicrob. Chemother.* 65, 2108–2115.
- Firth, K.J., Johnson, S.C., Ross, N.W., 2000. Characterization of proteases in the skin mucus of Atlantic Salmon (*Salmo salar*) infected with the salmon louse (*Lepeophtheirus salmonis*) and in whole-body louse homogenate. *J. Parasitol.* 86, 1199–1205.
- Gesto, M., Liu, D., Pedersen, L.-F., Meinelt, T., Straus, D.L., Jokumsen, A., 2018. Confirmation that pulse and continuous peracetic acid administration does not disrupt the acute stress response in rainbow trout. *Aquaculture*. 492, 190–194.
- Good, C., Davidson, J., Straus, D.L., Harper, S., Marancik, D., Welch, T., Peterson, B., Pedersen, L.-F., Lepine, C., Redman, N., Meinelt, T., Liu, D., Summerfelt, S., 2020. Assessing peracetic acid for controlling post-vaccination *Saprolegnia* spp.-Associated mortality in juvenile Atlantic salmon *Salmo salar* in freshwater recirculation aquaculture systems. *Aquac. Res n/a*. In Press.
- Hickman, W.S., 2002. Peracetic Acid and Its Use in Fibre Bleaching 32. pp. 13–27.
- Hushangi, R., Hosseini Shekarabi, S.P., 2018. Effect of a peracetic acid-based disinfectant on growth, hematology and histology of juvenile rainbow trout (*Oncorhynchus mykiss*). *Fishes*. 3, 10.
- Lazado, C.C., Timmerhaus, G., Pedersen, L.-F., Pittman, K., Soleng, M., Haddeland, S., Johansen, L.-H., Breiland, M.S.W., Rørmark, L., Mohammad, S., 2019. Peracetic acid as a potential treatment for amoebic gill disease (AGD) in Atlantic salmon-Stage 1. *Nofima rapportserie* 21 (2019), 54.
- Liu, D., Lazado, C.C., Pedersen, L.-F., Straus, D.L., Meinelt, T., 2020a. Antioxidative, histological and immunological responses of rainbow trout after periodic and continuous exposures to a peracetic acid-based disinfectant. *Aquaculture*. 734956.
- Liu, D., Lazado, C.C., Pedersen, L.-F., Straus, D.L., Meinelt, T., 2020b. Antioxidative, histological and immunological responses of rainbow trout after periodic and continuous exposures to a peracetic acid-based disinfectant. *Aquaculture*. 520, 734956.
- Luis, A.I.S., Campos, E.V.R., de Oliveira, J.L., Fraceto, L.F., 2019. Trends in aquaculture sciences: from now to use of nanotechnology for disease control. *Rev. Aquac.* 11, 119–132.
- Marchand, P.-A., Phan, T.-M., Straus, D.L., Farmer, B.D., Stüber, A., Meinelt, T., 2012. Reduction of in vitro growth in *Flavobacterium columnare* and *Saprolegnia parasitica* by products containing peracetic acid. *Aquac. Res.* 43, 1861–1866.
- Mehlhase, J., Grune, T., 2002. Proteolytic response to oxidative stress in mammalian cells. *Biol. Chem.* 383, 559–567.
- Nagasawa, K., Lazado, C.C., Fernandes, J.M., 2012. Validation of endogenous reference genes for qPCR quantification of muscle transcripts in Atlantic cod subjected to different photoperiod regimes. In: Muchlisin, Z.A. (Ed.), *Aquaculture*. IntechOpen.
- Nüsslein-Volhard, C., Singh, A.P., 2017. How fish color their skin: a paradigm for development and evolution of adult patterns. *BioEssays*. 39, 1600231.
- Pedersen, L.-F., Lazado, C.C., 2020. Decay of peracetic acid in seawater and implications for its chemotherapeutic potential in aquaculture. *Aquac. Environ. Interact.*
- Pedersen, L.-F., Pedersen, P.B., Nielsen, J.L., Nielsen, P.H., 2009. Peracetic acid degradation and effects on nitrification in recirculating aquaculture systems. *Aquaculture*. 296, 246–254.
- Pedersen, L.-F., Meinelt, T., Straus, D.L., 2013. Peracetic acid degradation in freshwater aquaculture systems and possible practical implications. *Aquac. Eng.* 53, 65–71.
- Pittman, K., Sourd, P., Ravnøy, B., Espeland, Ø., Fiksdal, I.U., Oen, T., Pittman, A., Redmond, K., Sweetman, J., 2011. Novel method for quantifying salmonid mucous cells. *J. Fish Dis.* 34, 931–936.
- Pittman, K., Pittman, A., Karlson, S., Cieplinska, T., Sourd, P., Redmond, K., Ravnøy, B., Sweetman, E., 2013. Body site matters: an evaluation and application of a novel histological methodology on the quantification of mucous cells in the skin of Atlantic salmon, *Salmo salar* L. *J. Fish Dis.* 36, 115–127.
- Soleng, M., Johansen, L.-H., Johnsen, H., Johansson, G.S., Breiland, M.W., Rørmark, L., Pittman, K., Pedersen, L.-F., Lazado, C.C., 2019. Atlantic salmon (*Salmo salar*) mounts systemic and mucosal stress responses to peracetic acid. *Fish Shellfish Immunol.* 93, 895–903.
- Straus, D.L., Meinelt, T., Liu, D., Pedersen, L.-F., 2018. Toxicity of peracetic acid to fish: variation among species and impact of water chemistry. *J. World Aquac. Soc.* 49, 715–724.
- Svein, L.R., Timmerhaus, G., Krasnov, A., Takle, H., Stefansson, S.O., Handeland, S.O., Ytteborg, E., 2018. High fish density delays wound healing in Atlantic salmon (*Salmo salar*). *Sci. Rep.* 8, 16907.
- Thorsen, D.K., 2019. Melanin-based Skin Pigmentation and Stress in Atlantic Salmon (*Salmo Salar*), Faculty of Biosciences. Norwegian University of Life Sciences, Ås, Ås, Norway.
- Vincent, A.T., Gauthier, J., Derome, N., Charette, S.J., 2019. The rise and fall of antibiotics in aquaculture. In: Derome, N. (Ed.), *Microbial Communities in Aquaculture Ecosystems: Improving Productivity and Sustainability*. Springer International Publishing, Cham, pp. 1–19.